

A review article on important clinical parameters of Dermoid CYST Management

Humera Bint Raees

Laparoscopic Gynae Surgeon and Specialist Obstetrician, Zulekha Hospital, Sharjah, United Arab Emirates

Abstract

Dermoid cyst is a benign and common ovarian neoplasm affecting women. Sources for this review article were taken from PubMed and other up-to-date databases covering the period from *Jan 2010 to Jan 2020*. Keywords for the search were “dermoid cyst” and “treatment”. A search of the literature revealed 113 full text manuscripts, from which 21 were relevant. In addition, another 56 relevant manuscripts identified in the reference lists of the above-mentioned 21 manuscripts were included in the study, although they had been published before 2020. Clinical considerations for dermoid cyst management are categorized as follows:

- Selection of the best choice of surgical treatment in dermoid cyst: laparoscopy or laparotomy;
- Procedure to exteriorize a dermoid cyst in laparoscopy;
- Selection of oophorectomy or cystectomy;
- Spillage of the cyst contents: prevention and treatment of the consequences if it does happen;
- Necessity of surgical treatment in dermoid cyst management;
- Ovarian torsion and other complications;
- Probability of malignancy in dermoid cyst

Keywords: dermoid cyst, treatment, laparoscopy, iran, laparotomy, ovary, malignancy

Introduction

Mature cystic teratoma (*dermoid cyst*) is a benign neoplasm that most commonly occurs in young women. The first step is to perform pelvic sonography. The main goal of sonography is to determine the probability of malignancy in ovarian mass and dermoid cyst. In 75% of cases, characteristic sonographic findings are present. Sometimes, a dermoid cyst is mistakenly regarded as malignant. This review aimed to clarify some clinical points of dermoid cyst management ^[1].

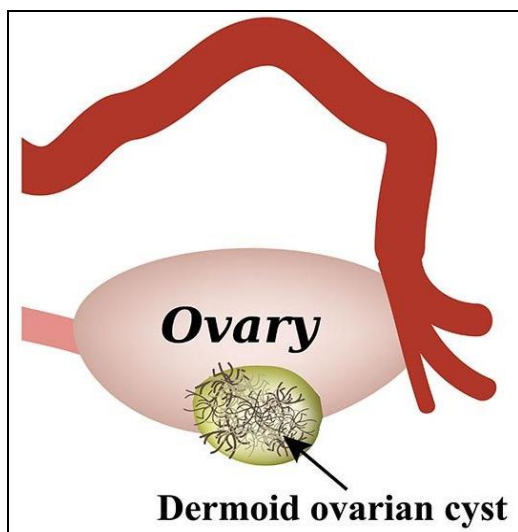


Fig 1

Methods

A search was conducted in PubMed and other up-to-date databases for English publications using the keywords “dermoid cyst” and “management” for available full text manuscripts from Jan 2010 to Jan 2020.

Data Synthesis

In the primary evaluation, based on titles and abstracts of 29 papers found in the PubMed database, 20 papers were excluded and from the 84 papers found in other up-to-date databases, 72 papers were excluded. Finally, 21 papers were reviewed in full text as well as in reference list to identify other potentially relevant papers.

56 relevant papers cited in the reference list of the above-mentioned 21 manuscripts were also reviewed and then included in the study, although they had been published before 2010.

Selection of the best choice of surgical treatment in dermoid cyst: laparoscopy or laparotomy?

Many trials have reported laparoscopy as a superior treatment in surgical management of dermoid cyst. The laparoscopic method is considered the gold standard of surgery in dermoid cyst management ^[2-6].

Advantages and disadvantages of the laparoscopic approach to dermoid cyst treatment are depicted in table below:

Table 1: Advantages and disadvantages of laparoscopic approach to dermoid cyst treatment

Advantages of the laparoscopic approach to dermoid cyst	Disadvantages of the laparoscopic approach to dermoid cyst
Less Bleeding	Longer Duration of Operation
Less Postoperative Pain	Higher Rate of Spillage
Less Need for Postoperative Analgesic	Higher Rate of Recurrence
Shorter Hospital Stay	Higher Cost (Individually)
Less Adhesion Formation	Increased Risk of Surgery
Better Cosmetic Results	Unique to Laparoscopy
Less Cost (Overall)	
Better Magnification	

When should laparotomy be considered in dermoid cyst management [7-9]?

1. Large mass controversy exists in the precise tumor size for which laparotomy is the recommended treatment. Some authors have recommended 10 centimeters as the cut-off size for laparotomy. There is evidence of solid components in the tumor mass and a suspicion of malignancy.
2. Bilateral cysts It is important in women older than 40 years to send specimens to the frozen section in cases of suspicious sonographic findings and high tumor markers.

Procedure for exteriorization of a dermoid cyst in laparoscopy:

One method for retrieval of a dermoid cyst is via the umbilical port under the bag. Contents of a low mass cyst can be extracted by suction and traction by forceps. Removal of the cyst through lateral ports or an extended incision might increase postoperative pain, take more recovery time, increase the probability of hernia development, cause epigastric vessel trauma, and be cosmetically detrimental.

Selection of Oophorectomy or Cystectomy

According to the sources [9], cystectomy is considered as dermoid cyst surgery of choice instead of oophorectomy. It has been indicated that each 1 mm² of ovarian surface includes about 35 primordial follicles in women in the age range of 11 - 34 years. Even in large dermoid cysts, there is about 3.7 cm³ volume of functional ovary in postoperative sonography. Thus, cystectomy is the first choice in the case of children and younger women. However, oophorectomy is the standard procedure in postmenopausal women.

In the case of premenopausal women, the considerations listed below affect the choice of treatment:

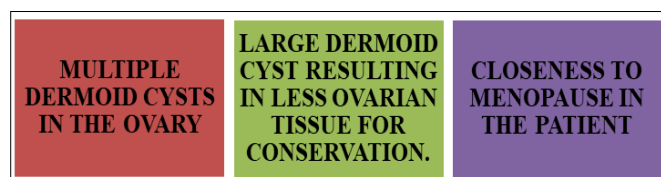


Fig 2

How might ovarian tissue be more preserved in cystectomy [10-17]?

In young women and children, preservation of ovarian tissue is important for fertility and future sexual development.

The techniques listed below are suggested for maximum preservation of ovarian tissue:

1. A combination of hydro-dissection and blunt dissection by laparoscopy instead of the traditional stripping technique.
2. Incision in the mesial side of the ovary: the mesial side of ovary is the point of connection of fimbria to ovary. Studies have revealed mesial side incision to better preserve ovarian function. Summarized advantages of mesial side ovarian incision are as follows:
 - Better preservation of ovarian tissue
 - Less probability of spillage and its consequences
 - Less procedure time due to better cleavage access, less bleeding, and easy cystectomy
 - Less electrocoagulation needed due to less bleeding.

Following dermoid cyst operation indices used to clarify remaining ovarian tissue and its function are listed below:

1. Visualization of remaining ovarian cortex by sonography reported as tissue volume
2. Measurement of fsh
3. Evaluation of basal antral follicle number
4. Measurement of ovarian size
5. Doppler velocimetry of peak systolic velocity, and
6. Measurement of anti-mullerian hormone (amh).

In expectant management and cases of ovarian preservation as well as in children with or without prediagnosed dermoid cyst, awareness of ovarian torsion should be considered. Wasting time on ovarian torsion diagnosis might result in ovarian tissue loss.

Spillage of the cyst contents: prevention and treatment of the consequences if it does happen [18-21]:

Spillage of cyst content is reported in 40% - 50% of laparoscopic cystectomy cases, which is highest spillage rate in this setting. Lower spillage rates in laparoscopic oophorectomy and even less spillage in laparotomy have been reported (10% - 15%). Spillage of dermoid cyst content might result in chemical peritonitis and adhesion formation. Chemical peritonitis is difficult to manage and may result in chronic pelvic pain. Fortunately, chemical peritonitis following spillage is a rare complication (0.2%).

Adhesion formation following spillage has not yet been properly defined. Some reports have favored less adhesion in laparoscopy in comparison with laparotomy.

In the case of spillage in the operation field, large volume peritoneal lavage by warm fluid should be done. Cold fluid may cause hypothermia and make fat-rich content difficult to wash out. Four techniques are suggested to reduce spillage rate:

1. Use of an endoscopic bag,
2. Mesial side incision in dermoid cyst probably due to thicker ovarian cortex at this point,
3. Gasless lift laparoscopic method, and
4. Less electro coagulation.

Is surgical management necessary in dermoid cyst [22-30]? Expectant management of dermoid cyst should be made according to the considerations listed below.

1. Pathognomonic sonography findings of dermoid cyst including

First, Rokitansky nodule (dermoid plug), which is a cyst containing highly echogenic nodule inside;
 Second, thin band-like echo in the cyst (dermoid mesh), which represents floating hair inside the cyst;
 Third; tip of the iceberg sign resulting from acoustic shadowing of the sebum on hair content of the cyst; and
 Fourth; fat-fluid level.

2. Negative color Doppler sonography: indicating low velocity and high resistance

1. Small sized dermoid cyst: that has been considered in most studies below 6 centimeters as small. There is less torsion in a smaller sized cyst in comparison with a large cyst; there is also lower rate of malignancy and lower growth rate.
2. Slow growth rate: annually less than 2 centimeters. Dermoid cyst is a slow growing cyst. Every year about 1.5 to 1.7mm growth rate is possible. The growth rate is close to zero in post menopause. In women of reproductive age, there is higher growth rate, probably due to the effect of hormones on sebaceous glands.
3. Negative tumor markers.
4. Asymptomatic condition
5. Children (in prepubertal stage) and adolescents due to sexual development and fertility preservation goals, follow-up is strongly considered.
6. Pregnancy
7. Medical co-morbidity with high probability of operative complications.

There is a lack of data-based evidence to formulate guidelines for intervention or expectant management. Risk of malignancy is below 1%. There is logical comparison between conservative management of myoma with below 1% malignancy rate and expectant management of dermoid cysts. It seems reasonable to individualize each case according to the patient's characteristics.

Ovarian Torsion and Other Complications

According to the sources [31], dermoid cyst is asymptomatic. In 3% - 4% of women, pelvic pain occurs usually due to ovarian torsion. The highest risk of torsion among cases of ovarian cyst belongs to dermoid cysts. The most probable cause of this tendency is high fat content, its weight and long pedicle. Nearly all dermoid cysts are complicated by torsion far from being large in size (more than 5 - 6 centimeters). Thus, cystectomy of dermoid cysts larger than 5cm can prevent this complication. Ovarian torsion may result in loss of ovary, rupture (rare) and fistulization. The treatment of choice in ovarian torsion is laparoscopy and detorsion for those in reproductive age and oophorectomy in postmenopausal women. Even if there is persistent black color of the ovary after detorsion procedure, oophorectomy is not indicated. Fixation of the ovary is not recommended.

Spontaneous rupture of a dermoid cyst is rare. If this happens, in its acute phase, shock and hemorrhage may occur. Chronic exposure to irritant content including sebaceous material and hair may result in granulomatous peritonitis.

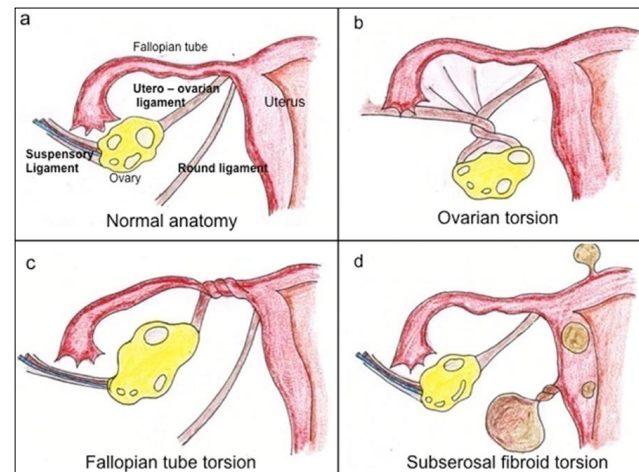


Fig 3

Autoimmune disorders are rare complications of dermoid cyst including anti-N-methyl-D-aspartate (NMDA) receptor encephalitis and autoimmune hemolytic anemia.

In the case of encephalitis, symptoms might be presented as acute psychosis and persistent seizure, more often seen in adults and the younger age group. Surgical resection of the cyst is the effective treatment of choice.

Pathophysiology of autoimmune hemolytic anemia is not known. In some cases, surgical removal of the cyst is an effective treatment.

Recurrence of dermoid cyst occurs in 3% - 4% of cases. Recurrence is more common in cases of laparoscopic treatment, probably due to unrecognized small cysts. Other predictive factors of recurrence are: young age (less than 30), large cyst size (8 cm or larger) and bilateral cyst. In a study, the presentation of 2 of these factors was associated with 21% risk of recurrence. A follow-up conducted 12 months after surgical treatment may diagnose recurrence. Most cases of recurrence happen in the first year.

Conclusion

According to the sources, dermoid cyst is the most common solid type tumor and the most common ovarian mass to occur at young age. Mature cystic teratoma with malignant degeneration occurs when somatic malignant transformation happens. Risk factors of malignant transformation in dermoid cyst are summarized in the following 4 considerations: age of over 45 years, cyst size of more than 10 cm, rapid growth and abnormal sonographic and Doppler findings including increased vascularity, hetero echo pattern, papillary projections and septation.

References

1. Patel MD. Ultrasound differentiation of benign versus malignant adnexal masses, 2016. Available from: <http://www.UpToDate.com>.
2. Sinha A, Ewies AA. Ovarian Mature Cystic Teratoma: Challenges of Surgical Management. *Obstet Gynecol Int*, 2016;2016:2390178. doi: 10.1155/2016/2390178. [PubMed: 27110246].
3. Morgante G, Ditto A, la Marca A, Trotta V, De Leo V. Surgical treatment of ovarian dermoid cysts. *Eur J Obstet*

- Gynecol Reprod Biol, 1998;81(1):47–50. [PubMed: 9846713].
4. Ferrari MM, Mezzopane R, Bulfoni A, Grijuela B, Carminati R, Ferrazzi E, *et al.* Surgical treatment of ovarian dermoid cysts: a comparison between laparoscopic and vaginal removal. *Eur J Obstet Gynecol Reprod Biol*, 2003;109(1):88–91. [PubMed: 12818451].
 5. Benezra V, Verma U, Whitted RW. Comparison of laparoscopy versus laparotomy for the surgical treatment of ovarian dermoid cysts. *Gynecol Surg*, 2005;2(2):89–92. doi: 10.1007/s10397-005-0091-y.
 6. Cristoforoni P, Palmeri A, Walker D, Gerbaldo D, Lay R, Montz FJ. Ovarian cystic teratoma: to scope or not to scope?. *J Gynecol Tech*, 1995;1(3):153–6.
 7. American College of O. ACOG Practice Bulletin. Management of adnexal masses. *Obstet Gynecol*, 2007;110(1):201–14. doi: 10.1097/01.AOG.0000263913.92942.40. [PubMed: 17601923].
 8. Medeiros LR, Stein AT, Fachel J, Garry R, Furness S. Laparoscopy versus laparotomy for benign ovarian tumor: a systematic review and meta-analysis. *Int J Gynecol Cancer*, 2008;18(3):387–99. doi: 10.1111/j.1525-1438.2007.01045.x. [PubMed: 17692084].
 9. Caspi B, Appelman Z, Rabinerson D, Zalel Y, Tulandi T, Shoham Z. The growth pattern of ovarian dermoid cysts: a prospective study in premenopausal and postmenopausal women. *Fertil Steril*, 1997;68(3):501–5. [PubMed: 9314922].
 10. Nezhat CR, Kalyoncu S, Nezhat CH, Johnson E, Berlanda N, Nezhat F. Laparoscopic management of ovarian dermoid cysts: ten years' experience. *JLS*, 1999;3(3):179–84. [PubMed: 10527327].
 11. Multani J, Kives S. Dermoid cysts in adolescents. *Curr Opin Obstet Gynecol*, 2015;27(5):315–9. doi: 10.1097/gco.0000000000000206.
 12. Muto MG. Management of an adnexal mass, 2016. Available from: <http://www.UpToDate.com>.
 13. Corrine KW. Ovarian development and failure (menopause) in normal women 2016. Available from: <http://www.UpToDate.com>.
 14. Agarwal P, Agarwal P, Bagdi R, Balagopal S, Ramasundaram M, Paramaswamy B. Ovarian preservation in children for adnexal pathology, current trends in laparoscopic management and our experience. *J Indian Assoc Pediatr Surg*, 2014;19(2):65–9. doi: 10.4103/0971-9261.129594. [PubMed: 24741207].
 15. Rogers EM, Allen L, Kives S. The recurrence rate of ovarian dermoid cysts in pediatric and adolescent girls. *J Pediatr Adolesc Gynecol*, 2014;27(4):222–6. doi: 10.1016/j.jpag.2013.11.006. [PubMed: 24656705].
 16. Lind T, Hammarstrom M, Lampic C, Rodriguez-Wallberg K. Anti-Mullerian hormone reduction after ovarian cyst surgery is dependent on the histological cyst type and preoperative anti-Mullerian hormone levels. *Acta Obstet Gynecol Scand*, 2015;94(2):183–90. doi: 10.1111/aogs.12526. [PubMed: 25287421].
 17. Morelli M, Mocciano R, Venturella R, Imperatore A, Lico D, Zullo F. Mesial side ovarian incision for laparoscopic dermoid cystectomy: a safe and ovarian tissue-preserving technique. *Fertil Steril*, 2012;98(5):1336–40 e1. doi: 10.1016/j.fertnstert.2012.07.1112. [PubMed: 22884658].
 18. Sharp HT. Evaluation and management of ruptured ovarian cyst, 2016. Available from: <http://www.UpToDate.com>.
 19. Koshiba H. Severe chemical peritonitis caused by spontaneous rupture of an ovarian mature cystic teratoma: a case report. *J Reprod Med*, 2007;52(10):965–7. [PubMed: 17977177].
 20. Zanetta G, Ferrari L, Mignini-Renzini M, Vignali M, Fadini R. Laparoscopic excision of ovarian dermoid cysts with controlled intraoperative spillage. Safety and effectiveness. *J Reprod Med*, 1999;44(9):815–20.
 21. Teng FY, Muzsnai D, Perez R, Mazdisnian F, Ross A, Sayre JW. A comparative study of laparoscopy and colpotomy for the removal of ovarian dermoid cysts. *Obstet Gynecol*, 1996;87(6):1009–13. [PubMed: 8649681].
 22. Hoo WL, Yazbek J, Holland T, Mavrellos D, Tong EN, Jurkovic D. Expectant management of ultrasonically diagnosed ovarian dermoid cysts: is it possible to predict outcome?. *Ultrasound Obstet Gynecol*, 2010;36(2):235–40. doi: 10.1002/uog.7610. [PubMed: 20201114].
 23. Muto MG. Patient education: ovarian cysts (Beyond the basics), 2016. Available from: <http://www.UpToDate.com/>.
 24. Guerriero S, Alcazar JL, Pascual MA, Ajossa S, Gerada M, Bargellini R, *et al.* Diagnosis of the most frequent benign ovarian cysts: is ultrasonography accurate and reproducible?. *J Womens Health (Larchmt)*, 2009;18(4):519–27. doi: 10.1089/jwh.2008.0997. [PubMed: 19361320].
 25. Malde HM, Kedar RP, Chadha D, Nayak S. Dermoid mesh: a sonographic sign of ovarian teratoma. *AJR Am J Roentgenol*, 1992;159(6):1349–50. doi: 10.2214/ajr.159.6.1442421. [PubMed: 1442421].
 26. Patel MD, Feldstein VA, Lipson SD, Chen DC, Filly RA. Cystic teratomas of the ovary: diagnostic value of sonography. *AJR Am J Roentgenol*, 1998;171(4):1061–5. doi: 10.2214/ajr.171.4.9762997. [PubMed: 9762997].
 27. Sheth S, Fishman EK, Buck JL, Hamper UM, Sanders RC. The variablesonographic appearances of ovarian teratomas: correlation with CT. *AJR Am J Roentgenol*, 1988;151(2):331–4. doi: 10.2214/ajr.151.2.331. [PubMed: 3293377].
 28. Tongsong T, Wanapirak C, Khunamornpong S, Sukpan K. Numerous intracystic floating balls as a sonographic feature of benign cystic teratoma: report of 5 cases. *J Ultrasound Med*, 2006;25(12):1587–91. [PubMed: 17121955].
 29. Patel MD. Pitfalls in the sonographic evaluation of adnexal masses. *Ultrasound Q*, 2012;28(1):29–40. doi: 10.1097/RUQ.0b013e31823c22a4. [PubMed: 22222866].
 30. Tongsong T, Luewan S, Phadungkiatwattana P, Neeyalavira V, Wanapirak C, Khunamornpong S, *et al.* Pattern recognition using transabdominal ultrasound to diagnose ovarian mature cystic teratoma. *Int J Gynaecol Obstet*, 2008;103(2):99–104. doi: 10.1016/j.ijgo.2008.06.02. [PubMed: 18718589].
 31. Raewyn C, Paul W. Management of congenital lingual dermoid cysts. *Int J Pediatr Otorhinolaryngol*, 2010;74(6):567–71. doi: 10.1016/j.ijpo

rl.2010.02.012. [PubMed: 20211495].